



International Journal of Research Publications

Expression of Matrix Metalloproteinase-9 (MMP-9) In Ameloblastoma's Histopathological Subtypes, Radiological Imaging and Tumor size

Mei Ika MC, Delyuzar, Joko SL*

*Anatomical Pathology Department Medical faculty Universitas Sumatera Utara, Jalan Universitas No.1 Gedung Abdul Hakim, Medan
20155, Indonesia*

Abstract

Background. Ameloblastoma is the most common odontogenic epithelial tumor. They are slow-growing, locally invasive and have various sizes, radiological imagings and histopathological subtypes. This tumor infiltrate the surroundings tissue by degrade the extracellular matrix, this activity can be seen based on the expression of MMP-9.

Objective. To investigate if there any difference in agresitivity of ameloblastoma based on MMP-9 expression in various histopathological subtypes, radiological imaging and tumor size.

Material and Methods. This is descriptive study with cross sectional approach. The samples of this study are medical records and slides/ paraffin blocks of patients that has been diagnosed as ameloblastomas at Haji Adam Malik General Hospital Medan. Ameloblastoma were stained by MMP-9 then evaluated by semiquantitative methods and related to histopathological subtypes, radiological imaging and tumor size.

Results. Based on data from 24 samples in this study showed all the samples were stained positively, 13 were weak expression and 11 were strong. Histopathological subtypes that found were follicular, plexiform, unilocular, extraosseus. Unilocular and extraosseus showed strong expression while follicular and plexiform showed various expression. The multilocular imaging showed mostly weak expression while the unilocular showed mostly strong expression, but not significant (p-value 0,537). For tumor size , 5 cm mostly showed strong expression, 5-10 cm mostly showed weak expression and > 10 cm showed equal strong and weak expression, but they had no significance (p-value 0,673).

Conclusion. There was no significant correlation between MMP-9 expression with ameloblastoma's radiological imaging

* Corresponding author. Tel.: +62-852-976-97691; fax: +62-618-211-746.
E-mail address: meikadr86@gmail.com

and tumor size. Plexiform type mostly had strong expression.

© 2018 Published by IJRP.ORG. Selection and/or peer-review under responsibility of International Journal of Research Publications (IJRP.ORG)

Keywords: ameloblastoma;MMP-9;histopathological subtype;radiological imaging;tumor size

1. Introduction

Ameloblastoma is a tumor from the odontogenic epithelium. Ameloblastoma can develop from the dental lamina, the enamel of the developing organ, the epithelium lining the odontogenic cyst and from the basal cells of the oral mucosa. Ameloblastoma generally grows slowly but locally invasive. Ameloblastoma is rare in children under the age of 10 years, its peak incidence is in the 3rd to 7th decades, where there is no difference in men and women. Ameloblastoma is most prevalent in China and Africa, followed by America and Canada. The global incidence is estimated to be 0.5 per one million population per year. While in Indonesia the incidence of ameloblastoma reaches 115 cases per year, at Haji Adam Malik Hospital in Medan reaching 40 cases in a period of 5 years. [1-4]

There are several types of radiological imaging of ameloblastoma such as multilocular (honeycomb and bubble soap) and unilocular imaging. Size of this tumour is varies, from 1- 8.5 cm, but can also exceed that size. Ameloblastoma subtypes based on histopathological features are divided into several subtypes, like solid / multicystic which are divided into follicular, plexiform, acanthomatous, desmoplastic, granular and basaloid types; unicystic; peripheral or extraosseous and metastizing ameloblastoma. Treatment of ameloblastoma can be divided into enucleation, curettage and resection, inadequate treatment or removal of the tumor results in a very high recurrence rate. Some studies said that inadequate treatment was a factor in the occurrence of malignant transformation in ameloblastoma. As is well known that ameloblastoma is an infiltrative tumor, where one of the ways this tumor infiltrates is by damaging the extracellular matrix. Until now ameloblastoma is categorized as a benign tumor, but its destructive / infiltrative characteristics and metastatic tendencies make ameloblastoma very interesting for further investigation.[1,4-8]

2. Material and Methods

This research is a descriptive analytic study with a cross sectional approach, which aims to analyze the MMP-9 expression in various histopathological subtypes, radiological imaging and tumour size of ameloblastoma tumors. The primary antibodies used were MMP-9 monoclonal antibody, anti-human mouse, R & D with 1: 100 dilution, for 60 minutes, then used secondary antibody PolyVue Plus™ Enhancer (Diagnostic Biosystems).

The sample in this study was sliced and paraffin blocks originating from tumor tissue which was diagnosed as ameloblastoma in the Anatomical Pathology Department of the USU Medical Faculty / H. Adam Malik General Hospital in Medan that met the inclusion and exclusion criteria. The slide which was diagnosed as ameloblastoma in haematoxylin and eosin staining was reviewed to determine histopathological subtypes, then the paraffin block was resliced and MMP-9 immunohistochemical staining was carried out. The results of immunohistochemical staining of MMP-9 were evaluated by researchers. MMP-9 expression is the appearance of brown color in the cell's cytoplasm at 10 high power fields, with 400x magnification (Olympus BX 51 microscope), where the expression is assessed by looking at the percentage of distribution and intensity of stained tumor cells. The percentage evaluation is 0 (0%), 1 (1-50%), 2 (> 50%), while the

coloring intensity is 0 (not expressed), 1 (weak), 2 (medium) and 3 (strong). Expressions were assessed by multiplying the distribution score and intensity with an interpretation of 0 (negative), 1,2,3 (weak positive), 4,6 (strong positive). Then analyzed statistically by the chi square test. The study was approved by the ethics committee of the Medical Faculty of the University of North Sumatra Medan with a letter number: 572 / DEP / KEPK FK USU-RSUP HAM / 2018.

3. Results

In this study 40 total cases of ameloblastoma patients diagnosed histopathologically in H. Adam Malik General Hospital Medan in 2012-2016 were obtained. However, there were only 24 cases of ameloblastoma patients who had complete clinical data (including tumor size and radiology) of all cases. Based on the sex of ameloblastoma patients, 12 samples were found in women (50%) and 12 in men (50%). The youngest age of ameloblastoma sufferers in this study was 10 years the oldest being 61 years, with the average age of patients was 34.1 years with a standard deviation of ± 13.5 . The smallest tumor size in this study was 1 cm and the largest was 20 cm, with an average size of 6.88 cm and a standard deviation of 4.47. The 5-10 cm tumor size was found most in this study, namely 13 cases (54.1%) followed by <5 cm in 7 cases (29.2%) and > 10 cm in 4 cases (16.7%). The radiological picture of multilocular ameloblastoma is more than unilocular. Multilocular, 18 cases (75%) were unilocular, 6 cases (25%). In this study there were only 4 histopathological subtypes of ameloblastoma from 9 histopathological subtypes available.

Table 1. Demographic characteristic of ameloblastoma's patients

No.	Characteristic	Total (n)	Percentage(%)
1.	Sex		
) Male	12	50
) Female	12	50
2.	Age (years); mean \pm SD	34,1 \pm 13,5	
3.	Size (cm); mean \pm SD	6,88 \pm 4,47	
4.	Size categories		
) < 5 cm	7	29,2
) 5-10 cm	13	54,1
) >10 cm	4	16,7
5.	Radiological imaging		
) Unilocular	6	6
) Multilocular	18	18
6.	Histopathological subtypes		
) Unilocular	1	4,2
) Follicular	14	58,3
) Plexiform	8	33,3
) Extraosseus	1	4,2
7.	MMP-9 expression		
) Weak	13	54,2
) Strong	11	45,8

The most commonly found histopathological subtypes of ameloblastoma are follicular type, about 14 cases (58.3%), followed by plexiform type as many as 8 cases (33.3%), unicystic type 1 case (4.2%) and extraosseous / peripheral type 1 case (4.2%). From all of the total samples after being stained with immunohistochemical MMP-9 staining, there were 13 weakly expressed cases (54.2%) and 11 strong expressions (45.8%).

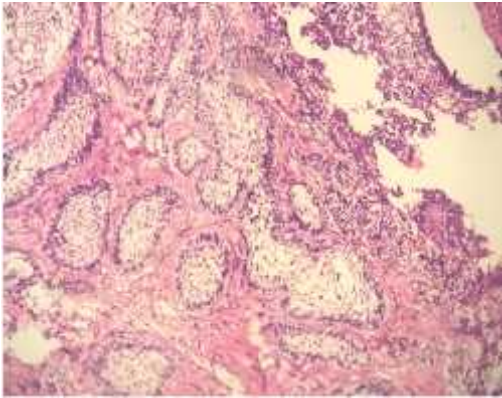


Fig.1 Ameloblastoma follicular subtype (HE,100x)

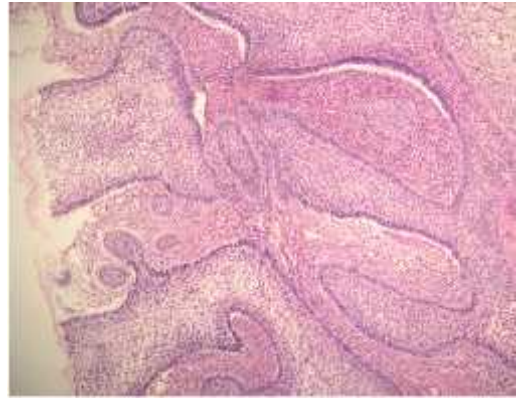

Fig.2 Ameloblastoma plexiform subtype (HE,100x)

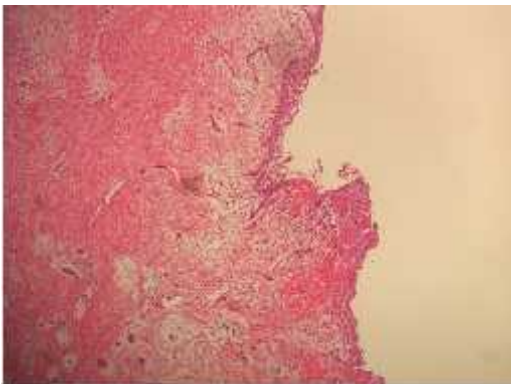


Fig.3 Ameloblastoma unicystic subtype (HE,100x)

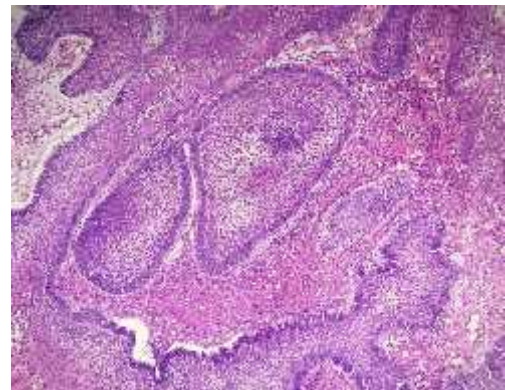


Fig.4 Ameloblastoma extraosseous subtype (HE,100x)

3.1. Distribution of ameloblastoma's histopathological subtypes based on expression of MMP-9

In this study, unilocular histopathological subtypes showed strong expression (1 case), follicular histopathological subtype showed 50% strong expression and 50% weak expression (7 cases each), plexiform histopathological subtype showed 75% weak expression and 25% strong expression (6 and 2 cases) while the extraosseous 100% histopathological subtype was strongly expressed (1 case) (Table 2).

Table 2. Distribution of ameloblastoma's histopathological subtypes based on expression of MMP-9

No.	Histopathological subtypes	MMP-9 Expression			
		Weak		Strong	
		N	%	N	%
1.	Unilocular	0	0	1	100
2.	Follicular	7	50	7	50
3.	Plexiform	6	75	2	25
4.	Extrasosseus	0	0	1	100

3.2. Distribution of ameloblastoma's radiological imaging based on expression of MMP-9

Unilocular ameloblastoma radiology with strong expression covers 66.7% (4 cases) while weakly expressed 33.3% (2 cases). Whereas in multilocular radiology images that were strongly expressed reached 38.9% (7 cases) while those with weak expression included 61.1% (11 cases). From the results of the chi-square statistics, there is no significant relationship between radiology and MMP-9 expression (p-value 0.537) (Table 3).

Table 3. Distribution of ameloblastoma's radiological imaging based on expression of MMP-9

No.	Radiological imaging	MMP-9 Expression				p-value
		Weak		Strong		
		n	%	N	%	
1.	Unilocular	2	33,3	4	66,7	0,537
2.	Multilocular	11	61,1	7	38,9	

3.3. Distribution of ameloblastoma's tumour size based on expression of MMP-9

In the tumor size category <5 cm 4 of the 7 cases were strongly expressed (57.1%), in the category of 5-10 cm tumor size only 5 of the 13 cases were strongly expressed (38, 5%) of eight of the cases (61, 5 %) weak expression. While tumors with a category > 10 cm were expressed as weak and strong as many, each of which was 2 cases (50%). From the results of chi-square statistics, there was no significant relationship between tumor size and MMP-9 expression (p-value 0.673) (Table 4).

Table 4. Distribution of ameloblastoma's tumour size based on expression of MMP-9

No.	Tumor size	MMP-9 Expression				<i>p-value</i>
		Weak		Strong		
		n	%	n	%	
1.	<5 cm	3	42,9	4	57,1	0,673
2.	5-10 cm	8	61,5	5	38,5	
3.	>10 cm	2	50.0	2	50.0	

4. Discussion

In this study there were 40 cases of ameloblastoma recorded in the medical record of the General Hospital of Haji Adam Malik Medan from 2012-2016 but who met the inclusion and exclusion criteria were 24 cases. From the 24 samples of ameloblastoma patients, there were as many men as women. The data obtained is in accordance with previous research by Setiady, 2013 and Singh et. al., 2010 and WHO also stated that there were no significant differences for men and women [1,8]. This shows that there is no difference in risk factors between men and women. Based on the origin of these tumors, in which WHO stated that ameloblastoma is thought to have a relation with tooth development where the development of teeth has a process that is not different for men and women. The youngest age of ameloblastoma patients

found in this study is 10 years with the oldest age of 61 years with an average age of 34.1 years and standard deviation of ± 13.5 . According to WHO and Neville ameloblastoma can occur in decades 3-7 of life, with peak incidence at the age of 30-40 years, and rarely occurs under the age of 10 years [1,5]. This is consistent with the data obtained in this study, and is similar to the research conducted by Setiady (2013)[2]. This can be attributed to the age of eruption of third molars, where third molars erupted in the third decade of life. This is quite different from what was written in the WHO where the incidence of ameloblastoma covers the 3rd to 7th decades, older age (5th to 7th decade) shows there are factors other than non-erupting third molars which affect the occurrence ameloblastoma. Ameloblastoma's tumor size in this study was more commonly found in tumors measuring 5-10 cm (medium size) about 13 cases, with the largest size (> 10 cm) in only 4 cases, while those measuring < 5 cm were only 7 cases. This is quite different from previous research by Singh, 2010 which showed that ameloblastoma had the largest size > 10 cm, (27 cases /67.5%), followed by ameloblastoma measuring 5-10 cm (25%) and ameloblastoma with size < 5 cm in 3 cases (7.5%) [8]. Many ameloblastoma sufferers in Indonesia are found in this medium, showing a low level of public awareness in examining themselves when there are painless lumps in themselves, supported by socioeconomic factors, where the cost of medical examinations is still considered expensive by the Indonesian people, most of whom are at middle to lower economy.

Radiology images of ameloblastoma in this study were more commonly found in multilocular radiology than unilocular. The results of this study are in line with the results of Singh's research, 2010 and WHO and Neville who stated that most ameloblastoma radiology is multilocular. MMP-9 is expressed in all samples, both in tumor cells and stroma, in the cytoplasm of cell. In this study 11 samples were strongly expressed (9 cases with a score of 4 and 2 cases with a score of 6) and 13 weakly expressed samples (score 2). The highest score is expressed in the follicular and plexiform subtypes. The expression of MMP-9 in various histopathological subtypes of ameloblastoma in this study showed that for the unilocular and extraosseous subtypes each was strongly expressed (100%). Whereas for follicular histopathology subtypes found the same number of cases that were expressed strong and weak, ie each of 7 cases. For the plexiform subtype, more are expressed weakly (6 cases) than those with strong expression (2 cases). Based on research conducted by Florescu A, et al (2012) which states that the most common type is follicular type, similar to this study, but in the Florescu A study, the most reactive (strong expression) of MMP-9 was the subtype acanthomatous and weakly expressed ones are granular types. The results of this study are also quite different from the research conducted by Anne R, et al (2014) which states that all of the ameloblastoma samples he studied express MMP-9 with moderate to strong expressions, of which the most strongly expressed are mixed type (83.3 %) followed by plexiform type (82.4%). In this study all samples expressed MMP-9 which showed that ameloblastoma was indeed very potential in destroying the extracellular matrix. However, in this study the most strongly expressed were follicular histopathological subtypes, but on the one hand this subtype was the most weakly expressed, where the plexiform subtype which was strongly expressed was only 25%. Whereas for the unilocular and extra-osseous subtypes all are strongly expressed, only because the sample in each of these subtypes is only 1, making it unable to be compared. This is quite in line with the research conducted by Da Silva, et al (2016) where it was stated that MMP-9 was more expressed in the solid type rather than unicystic ameloblastoma stroma [5,8,9-13]. From the data in this study, there were various expression of MMP-9 in ameloblastoma's histological subtypes.

In this study, ameloblastoma tumors with multilocular radiology were more weakly expressed than strongly expressed (61.1%: 38.9%) whereas ameloblastoma tumors with unilocular radiology were more strongly expressed than weak (66.7%: 33.3%). However, there was no significant difference between the two radiological images of MMP-9 expression (p-value 0.537). MMP-9 expression in unilocular radiology was more strongly expressed than multilocular which was more weakly expressed. This shows there is no aggressiveness difference in ameloblastoma with unilocular or multilocular radiology, in other words the aggressiveness of ameloblastoma is difficult to determine based on its radiological imaging.

Large size ameloblastoma (> 10 cm) were expressed equally between weak and strong. While for small sizes (<5 cm) are expressed more strong than weak (57.1%: 42.9%) and medium size (5-10 cm) are expressed more weak than strong (61.5%: 38 , 5%). From the results of the chi-square statistics, there was no significant relationship between tumor size and MMP-9 expression (p-value 0.673). Researchers also assume that the size of the ameloblastoma tumor cannot stand alone, should be accompanied by the duration of how long the tumor has occurred, so that the tumor growth rate can be known, because a 10 cm tumor that occurs within 2 years is different from a 10 cm tumor which occurs in just 6 months. However, this cannot be investigated in this study because of the limited data in the medical records of patients who did not include this. So far there have been no studies linking MMP-9 expression to ameloblastoma tumor size, so this study cannot be compared with previous studies.

5. Conclusion

There was no difference in aggressiveness of ameloblastoma based on the radiological imaging and size of the tumour. There were various MMP-9 expressions histological subtypes of ameloblastoma.

Acknowledgement

We acknowledge to all staff and residents of the Anatomical Pathology Department, University of North Sumatra / H. Adam Malik General Hospital, Medan, Indonesia for the support.

References

1. Vered M, Heikinheimo K, Shear M, Muller S. Ameloblastoma. In: Naggar AK, Chan JK, Grandis JR, Takata T, Slootweg PJ. Editors. World Health Organization Classification of Tumours Pathology and Genetics Head and Neck Tumours. France: IARC Press; 2017.p. 215-219
2. Setiady, DR. Kajian prevalensi ameloblastoma berdasarkan usia, regio, jenis kelamin, tipe histopatologi anatomis dan penatalaksanaannya di RSD DR. Soebandi jember tahun 2008-2012.Desember 2013
3. Rudiana, Sandini SU, Vitria EE, Santosa TI. Profile of ameloblastoma from a retrospective study in jakarta, Indonesia. Journal of Dentistry Indonesia.2011, Vol.18, No.2, 27-32
4. Li Y, Han B, Jiang-Li L. Prognostic and proliferative evaluation of ameloblastoma based on radiographic boundary. International Journal of oral science (2012)4,30-33
5. Slootweg PJ. Dental pathology a practical introduction. Berlin: Springer;2007.p. 59-61
6. Neville BW, Damm DD, Allen CM, Bouquot JE. Oral & Maxillofacial pathology second edition. Philadelphia: WB Saunders company.2002.p. 611-620
7. Soames JV, Southam JC. Oral Pathology 4th Ed. Oxford: Oxford University Press;2005.p.9-18
8. Singh V, Dhasmana S, mohammad S, DwivediC. Clinicopathological study and treatment outcome of 40 cases of ameloblastoma- a seven year retrospective report. World articles in ear, nose and throat.2010
9. Cui D, Naftal JP, Daley WP, Lynch JC, Haines DE, Yang G, et.al. Atlas of histology with functional &critical correlations. Philadelphia: Lippincott & Wilkins.2011.p. 266-278
10. Beena VT, Choudary K, Heera R, Rajeev R, Sivakumar R, Vidhyadharan K. Peripheral ameloblastoma: a case report and review of literature. Hindawi Publishing Corporation. Case Report in Dentistry Volume 2012. Article ID 571509
11. Anne R, Krisnuhoni E, Chotimah C, Latief BS. Matrix metalloproteinase-9 (MMP-9) expression in different subtypes of ameloblastoma. J.Maxillofac.oral surg.2014;13(3):281-285
12. Florescu A, Margarritescu CL, Simionescu CE, Stepan A. Immunohistochemical expression of MMP-9, TIMP-2, E-Cadherin and vimentin in ameloblastomas and their implication in the local aggressive behavior of these tumors. Rom J Morphol Embryol 2012. 53(4):975-984

13. Da Silva AD, Nobrega TG, Saudades AW, Otero MI, Danilevich CK, Magnusson AS, et al. Ameloblastic neoplasia spectrum a cross-sectional study of MMPs expression and proliferative activity. Oral surgery oral medicine oral pathology and oral radiology.2016 Apr;121(4):396-401