

## Correlation of MUCIN1 immunohistochemical expression and MUCIN1 expression immunoreactivity pattern on histopathological grading of prostate adenocarcinoma

Johan Sahmulia, Delyuzar, Lidya Imelda Laksmi, Joko S Lukito, T Ibnu Alferraly  
Jo\_muthiah@yahoo.co.id

Department of Anatomical Pathology, Faculty of Medicine,  
Universitas Sumatera Utara, Medan, Indonesia.

### ABSTRACT

**Background:** Prostate cancer was the cause of death for around 358,989 (3.8%) of all cancer deaths in men in 2018. In Indonesia in 2020 there were around 7.4% of new cases of prostate cancer from all malignancies and about 2.1% of them end in death. MUC1 is a transmembrane glycoprotein that can be expressed in prostate adenocarcinoma. Several studies have shown that excessive and aberrant MUC1 expression can be found in prostate malignancies with a worse degree of malignancy. In addition, recently MUC1 is also considered to be a therapeutic target in prostate malignancy because MUC1 plays a role in cell proliferation, apoptosis and cell adhesion, so several studies are being carried out to determine the effectiveness of this protein as an alternative treatment for prostate malignancy.

**Objective:** To examine MUC1 expression and the immunoreactivity pattern of MUC1 expression on histopathological grading of prostate adenocarcinoma

**Materials and Method:** This research is an analytic study with a cross sectional approach. The sample in this study was a prostate adenocarcinoma slide stained with MUC1 immunohistochemistry which was assessed for its expression in three categories, namely negative, weak positive and strong positive and the immunoreactivity pattern of expression with three patterns, namely apical, diffuse cytoplasm and mixed.

**Result:** There is no correlation between MUC1 expression and immunoreactivity pattern on histopathological grading of prostate adenocarcinoma.

**Keywords:** prostate adenocarcinoma, grade group Gleason, MUC1

### 1.Introduction

Prostate adenocarcinoma is a malignancy of the prostate gland that is commonly found in men. Adenocarcinoma is an invasive carcinoma, consisting of neoplastic prostate epithelial cells with secretory cell differentiation consisting of various histomorphological features such as glandular, cord, single cell, sheet and without the presence of basal cells in the glandular structure.<sup>1</sup>

Prostate cancer was the cause of death for about 358,989 (3.8%) of all cancer deaths in men in 2018. The highest mortality rate was recorded in Middle America at 10.7% per 100,000 men, followed by Australia and New Zealand is 10.2% and West Europe 10.1%. The lowest rates were reported in Asian countries, covering South-Middle Asia at around 3.3%, East Asia 4.7% and Southeast Asia 5.4%. North Africa has a prostate cancer death rate of about 5.8% per 100,000 men. One third of prostate cancer deaths occurred in Asia (33.0% or 118,427 deaths, followed by Europe at 29.9% or 107,315 deaths). Death rates from prostate cancer increase with age, and nearly 55% of all prostate cancer deaths occur after 65 years old.<sup>2,3</sup>

According to Sanni, the incidence of prostate adenocarcinoma at the Haji Adam Malik General Hospital Medan in the period 2014 - 2016 was 71 cases. According to GLOBOCAN, in 2020 in Indonesia there are about 7.4% of new cases of prostate cancer from all existing malignancies and about 2.1% of prostate cancer patients end up dying.<sup>4,5</sup>

In determining the prognosis of prostate adenocarcinoma, the World Health Organization (WHO) uses the Gleason group histopathological grading system. Until now, the prognostic value of prostate adenocarcinoma based on the Gleason grade group is still a strong indicator and plays an important role in the treatment of prostate cancer. The Gleason group grade system is based on prostate cancer behavior from several levels of the Gleason score, consisting of 5 grade groups, starting from grade group 1 with good behavior to grade group 5 with the worst behavior.<sup>1</sup>

MUCIN1 (MUC1) is a transmembrane mucin glycoprotein that is expressed on almost all epithelial cell surfaces. MUC1, also known as polymorphic epithelial mucin, is a group of high molecular mass glycoproteins. One important feature of the MUC1 gene is its polymorphism. The second exon expressed in the gene encoding MUC1 is derived from a variable number of tandem repeats (VNTR), and each VNTR consists of the 20-amino acid peptide VTSAPDTRPAPGSTAPPAHG, which is the major antigenic determinant in this region. Usually MUC1 is weakly expressed in normal adenocytes, is mainly localized on the surface of glandular cells or in excretory masses of glandular cavities, and is not recognized by the host immune

system. It has been found that aberrant expression of MUC1 is due to misglycolization or incomplete glycolization, in many tumor tissues including prostate. This abnormal MUC1 molecule indicates that the new protein epitope or carbohydrate antigen, is distributed around the surface of cancer cells, and can be recognized by the immune system as a tumor related antigen.<sup>6,7</sup>

Several recent studies suggest that MUC1 continues to be an attractive target because of its frequency of overexpression and aberration in cancer and its demonstrable immunogenicity. In prostate malignancy itself, research for MUC1 is still being carried out, both as a determinant of prognosis and as immunotherapy for prostate adenocarcinoma. According to the research of Eminaga et al., that there is a relationship between MUC1 expression and the degree of malignancy of prostate adenocarcinoma. Meanwhile, according to O'Connor et al. and Genits et al. There is no relationship between MUC1 expression and the degree of malignancy of prostate adenocarcinoma.<sup>8,9,10,11</sup>

Immunoreactivity pattern is a picture or place where immunohistochemical appearances appear on tumor cells or malignancies. The immunoreactivity pattern of MUC1 expression in several studies states that MUC1 can be displayed in the apical, diffuse cytoplasm and apical + diffuse cytoplasm (mixed) regions of tumor cells.<sup>9,10,12</sup> According to the study of Schut et al. MUC1 immunoreactivity pattern in malignant prostate tissue tends to have a diffuse cytoplasmic pattern compared to the apical pattern.<sup>13</sup> Meanwhile, according to O'Connor et al. Prostate adenocarcinoma has 3 patterns of MUC1 immunoreactivity, namely apical, diffuse and mixed.<sup>9</sup> Likewise, research conducted by Garbar et al., found that the immunoreactivity pattern of MUC1 expression in prostate adenocarcinoma can be displayed in the apical, cytoplasm and global regions of tumor cells.<sup>14</sup> Rabiau et al. conducted a study of MUC1 expression in prostate adenocarcinoma and only had an immunoreactivity pattern in the cytoplasm, while the other preparations could not know the immunoreactivity pattern of MUC1 expression in prostate adenocarcinoma.<sup>15</sup>

This study aims to analyze the correlation between MUC1 expression and expression immunoreactivity pattern on histopathological grading of prostate adenocarcinoma based on the Gleason grade group.

## 2. Material dan Methods

We studied prostate adenocarcinoma slides by hematoxylin-eosin staining. To exclude benign prostate lesions, p63 immunohistochemical staining was performed to assess basal cells. In addition, p63 immunohistochemistry and AMACR were used to exclude prostatic intraepithelial neoplastic lesions. All slides of prostate adenocarcinoma with MUC1 immunohistochemical staining were carried out at the Laboratory of Anatomic Pathology, Faculty of Medicine, USU and H. Adam Malik Hospital, Medan.

This research is an analytic study with a cross sectional design to analyze the relationship between MUC1 immunohistochemical expression and MUC1 expression immunoreactivity pattern on histopathological grading of prostate adenocarcinoma. Assessment of MUC1 immunohistochemical expression by looking at the appearance of brown color in the cytoplasm of tumor cells which is indicated by negative (-) if it fails to display brown color, positive (+) weak if it can display brown color with weak intensity, positive (+) strong if it can display brown color intense. The immunoreactivity pattern of MUC1 expression was assessed by the location of MUC1 expression at three locations. Apical, which is the appearance of a brown color in the apical area of tumor cells. Diffuse cytoplasm, which is the appearance of brown color in the cytoplasm of tumor cells. Mixed, ie the appearance of brown color both at the apical and in the cytoplasm of tumor cells.

## 3. Result

There were 34 samples of prostate adenocarcinoma patients who met the inclusion and exclusion criteria. All samples were obtained from surgery, 31 cases (91.2%) were from Transurethral resection prostatectomy (TURP) and 3 cases (8.8%) were from Radical Prostatectomy. Based on medical record data, it was found that the sample in this study had an average age of 64.97 years, with the youngest age being 43 years and the oldest being 91 years.

The highest number of patients with prostate adenocarcinoma was at the age of 60 years, namely 11 patients (32.4%) and > 60 years as many as 23 patients (67.6%). (Table 1)

<b>Table 1.</b> Sample characteristic distribution		
Characteristics of Patients	Amount (n)	Percentage (%)
Age		
≤ 60 tahun	11	32.4
> 60 tahun	23	67.6
Grading		
Grade group 1	3	8.8
Grade group 2	8	23.5
Grade group 3	2	5.9
Grade group 4	8	23.5
Grade group 5	13	38.2
MUC1 expression		
Negative	0	0.0
Weak	11	32.4
Strong	23	67.6
Immunoreactivity pattern		
MUC1 expression		
Apical	9	26.6
Diffuse cytoplasmic	20	58.8
Mixed	5	14.7

A total of 34 samples of prostate adenocarcinoma, negative immunohistochemical expression of MUC1 was not found. While the positive expression was weak in 11 cases (32.4%) and strong positive in 23 cases (67.6%). From 34 samples of prostate adenocarcinoma, apical MUC1 immunohistochemical expression pattern was found in 9 cases (26.6%), diffuse cytoplasm in 20 cases (58.8%) and mixed in 5 cases (14.7%). (Table 1)

**Table 2.** Characteristic distribution of MUC1 immunohistochemical expression relationship to histopathological grading of prostate adenocarcinoma

Variable	Histopathological grading of prostate adenocarcinoma					Total	P value*
	Grade group 1	Grade group 2	Grade group 3	Grade group 4	Grade group 5		
Negative	0 (0.0)	0 (0.0)	0 (0.0)	0 (0.0)	0 (0.0)	0 (0.0)	0,342
Weak	1 (2.9)	4 (11.8)	0 (0.0)	3 (8.8)	3 (8.8)	11 (32.4)	
Strong	2 (5.9)	4 (11.8)	2 (5.9)	5 (14.7)	10 (29.4)	23 (67.6)	
Total	3 (8.8)	8 (23.5)	2 (5.9)	8 (23.5)	13 (38.2)	34 (100.0)	

\*) Correlation test Somers'd

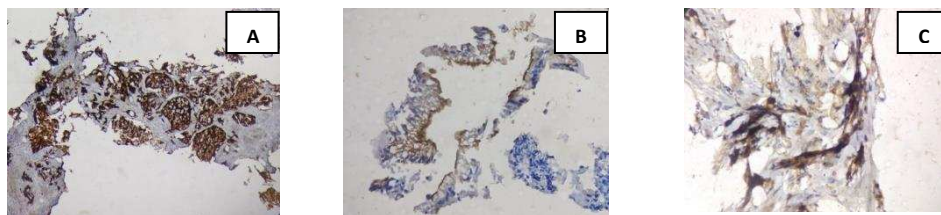
Based on table 2 above, after the Somers'd correlation statistical test was carried out, a p value of 0.342 ( $p > 0.05$ ) showed that the correlation between the immunohistochemical expression of MUC1 and the histopathological grading of prostate adenocarcinoma was not significant. Therefore, there was no correlation between the immunohistochemical expression of MUC1 on histopathological grading of prostate adenocarcinoma.

**Table 3.** Distribution of characteristics of the correlation between the pattern of immunoreactivity of MUC1 immunohistochemical expression on histopathological grading of prostate adenocarcinoma

Variable	Histopathological grading of prostate adenocarcinoma					Total	pvalue*
	Grade group 1	Grade group 2	Grade group 3	Grade group 4	Grade group 5		
Apical	1 (2.9)	2 (5.9)	2 (5.9)	0 (0.0)	4 (11.8)	9 (26.5)	> 0,05
Diffuse cytoplasmic	1 (2.9)	4 (11.8)	0 (0.0)	8 (23.5)	7 (20.6)	20 (58.8)	
Mixed	1 (2.9)	2 (5.9)	0 (0.0)	0 (0.0)	2 (5.9)	5 (14.7)	
Total	3 (8.8)	8 (23.5)	2 (5.9)	8 (23.5)	13 (38.2)	34 (100.0)	

\*) Correlation test Eta

Based on table 3 above, after the Eta correlation statistical test was performed, p value > 0.05 was obtained, indicating that the correlation between the immunohistochemical expression pattern of MUC1 and the histopathological grading of prostate adenocarcinoma was not significant. Therefore, there was no correlation between the immunohistochemical expression pattern of MUC1 on histopathological grading of prostate adenocarcinoma.



**Figure.** A. Strongly positive diffuse cytoplasmic MUC1 expression, B. Apically strong positive MUC1 expression, C. Diffuse cytoplasmic weakly positive MUC1 expression.

#### 4. Discussion

In all samples of prostate adenocarcinoma studied, all of them were positively expressed on MUC1 immunohistochemical staining. This is consistent with the literature that in prostate adenocarcinoma, MUC1 expression occurs due to hypoglycosylation of nuclear glycans. The process of MUC1 presentation to the surface of epithelial cells starts from the transcription process in the cell nucleus. After the transcription process is complete, MUC1 leaves the cell nucleus and enters the cytoplasm to undergo the process of translation and maturation. After MUC1 matures, it will then be stored in the endoplasmic reticulum and then transported into the Golgi apparatus. In the Golgi apparatus, MUC1 undergoes a glycosylation process. Some of the glycosylated MUC1 will be presented to the cell surface as a response that comes from the environment around the cell. In malignancy, misglycosylation occurs causing the glycosylation process to take place more and repeatedly so that MUC1 expression will increase, which we call MUC1 overexpression, this is what happened in prostate adenocarcinoma in this study.<sup>16,17</sup>

Based on the immunoreactivity pattern of MUC1 expression, the majority of samples as many as 20 had an immunoreactivity pattern of MUC1 expression in the diffuse cytoplasm. This is consistent with the study conducted by Schut et al., that the immunoreactivity pattern of MUC1 expression in malignant prostate tissue tends to have a diffuse cytoplasmic pattern. According to the literature, the immunoreactivity pattern of MUC1 expression occurs due to aberrant glycosylation of MUC1 in malignancy. Under normal circumstances MUC1 is located on the apical surface of epithelial cells, which functions as a physical barrier that protects epithelial cells from external disturbances such as exposure to toxins, microorganisms and other forms of external

stress. While in malignancy, due to the irreversible loss of polarity, MUC1 is not only displayed at the apical point of the cell, but also appears in the cytoplasm..<sup>13,17</sup>

In this study, all samples were positively expressed by MUC1 immunohistochemistry and none were negatively expressed. This is in accordance with research conducted by Eminaga et al., O'Connor et al. and Genits et al., who found positive MUC1 expression in prostate adenocarcinoma. In the distribution of MUC1 expression based on the Gleason grade group (table 4.2) it was found that the strongest positive expression of MUC1 was found in grade group 5 compared to other grade groups. This according to the researchers is related to poor gland differentiation in grade group 5 which consists of Gleason 5 pattern gland differentiation. As the researchers described above, irreversible loss of polarity in prostate adenocarcinoma causes MUC1 overexpression in tumor cells. However, when statistical tests were carried out to find the correlation between MUC1 expression and prostate adenocarcinoma grading, there was no significant relationship between the two. Researchers suspect this is due to the difference between the definition of the Gleason group grade system and the Gleason grade. In grade group 4, it consists of 3 combinations of Gleason grades, namely 4+4=8, 3+5=8 and 5+3=8, in which there are also 3 differentiation patterns, namely the Gleason pattern 3,4 and 5. In grade group 5, there were also 3 combinations of Gleason grades, namely 4+5=9, 5+4=9 and 5+5=10, in which there were 2 differentiation patterns, namely the Gleason pattern 4 and 5. MUC1 was associated with grading of prostate adenocarcinoma according to the Gleason grade group, not by Gleason grade or Gleason score. Because at first the researchers thought to know the prognosis of a prostate adenocarcinoma apart from the Gleason grade group, it could also be seen through the immunohistochemical expression of MUC1, but after statistical tests were carried out on the relationship between MUC1 expression and the Gleason grade group, there was no correlation between the two..<sup>1,9-11</sup>

In addition, in a previous study the correlation between MUC1 expression in prostate adenocarcinoma used the Gleason score system which is the sum of 2 Gleason patterns, while in this study the correlation between MUC1 expression in prostate adenocarcinoma used the Gleason grade group system. The Gleason grade group is the system used by WHO to determine the prognostic value of prostate adenocarcinoma in the 2016 WHO Classification of Tumors of the Urinary System and Male Genital Organ of prostate..<sup>1,9-11</sup>

According to the literature, strong positive expression tends to be found in poorly differentiated tumors, but the results of this study also found strong positive MUC1 expression in well differentiated tumors. This was also found in previous studies, this was due to the different glycosylation levels of MUC1 in each sample, as previously mentioned that MUC1 is a transmembrane glycoprotein resulting from the glycosylated variable number of tandem repeats (VNTR) around 50-90. % on the carbohydrate side chain..<sup>9-11,18</sup>

Aberrant MUC1 expression in prostate adenocarcinoma was found in 3 immunoreactivity patterns of MUC1 expression, namely apical, diffuse and mixed cytoplasm. This is consistent with the study by O'Connor et al., that prostate adenocarcinoma has 3 patterns of MUC1 expression immunoreactivity, namely apical, diffuse and mixed. Based on table 4.3, it was found that the pattern of diffuse cytoplasmic MUC1 immunoreactivity was dominated in grade groups 4 and 5, and all prostate adenocarcinomas with grade group 4 had a diffuse pattern of correlation MUC1 immunoreactivity. Although the statistical test did not find a relationship between the immunoreactivity pattern of MUC1 expression and the Gleason grade group, the results obtained confirm the hypothesis of previous researchers because in previous studies no one has ever looked for a correlation between these two variables..<sup>9,13-15</sup>

## 5. Conclusion

There was no correlation between MUC1 expression and the immunoreactivity pattern of MUC1 expression on histopathological grading of prostate adenocarcinoma in the Gleason grade group system.

## Acknowledgement

We acknowledge to all staff and residents of the Department of Pathology Anatomics, Faculty of Medicine, Universitas Sumatera Utara / Haji General Hospital, Malik Medan Medan.

## References

- (1) Humphrey PA, Amin MB, Berney DM, Bills A, Cao D, Cheng L, et al. Acinar Adenocarcinoma in: Moch H, Humphrey PA, Ulbright TM, Reuter VE, editors. WHO Classification of Tumor: WHO Classification of Tumors of the Urinary System and Male Genital Organ. Lyon: IARC Press; 2016. pp.138-61.
- (2) Bray F, Ferlay J, Soerjomataram I, Siegel RL, Torre LA, Jemal A. Global Cancer Statistics 2018. GLOBOCAN Estimates Incidence and Mortality Worldwide for 36 Cancers in 185 Countries. CA Cancer J Clin. 2018;68(6).
- (3) Rawla P. Epidemiology of Prostate Cancer. Word J Oncol 2019; 10(2) : pp 63-89.
- (4) International Agency for Research on Cancer. Indonesia, Source : Globocan 2020 Available from : <https://gco.iarc.fr/today/data/factsheets/populations/360-indonesia-fact-sheets.pdf>. (Accessed 10th February 2021).
- (5) Sanni. Hubungan Kadar Protein Specific Antigen dengan Gleason Score pada Penderita Adenocarcinoma Prostate Di RSUP.H. Adam Malik. Available from:<http://repositori.usu.ac.id/handle/123456789/3818> (Accessed 23th January 2021)
- (6) Khemiri M, Doghri R, Mrad K, Friedrich K, Oeslati R. Mucin-1 expression and localization in epithelial cells shows characteristic and distinct patterns in inflammatory bowel diseases and colorectal cancer. Int J Clin Exp Pathol. 2019; 12(5): pp 1731-37.
- (7) Papaditriou JT, Burchell J, Miles DW, Dalziel M. MUC1 and Cancer. Biochimica et Biophysica Acta 1455 .1999 : pp 301-13.
- (8) Rivalland G, Loveland B and Mitchell P. Update on Mucin-1 immunotherapy in cancer: a clinical perspective. Expert Opinion on Biological Therapy. 2015; 15(12): pp 1773-87.
- (9) O'Connor JC, Julian J, Lim SD, Carson DD. MUC1 expression in human prostate cancer cell lines and primary tumors. Prostate Cancer and Prostatic Disease. 2005; 8: pp 36-44.
- (10) Eminaga O, Wei W, Hawley SJ, Auman H, Newcomb LF, Simko J, et al. MUC1 Expression by Immunohistochemistry Is Associated with Adverse Pathologic Features in Prostate Cancer: A Multi-Institutional Study. PloS ONE .2016; 11(11): pp 1-12.
- (11) Genitsch V, Zlobec V, Thalmann GN, Fleischmann A. MUC1 is upregulated in advanced prostate cancer and is an independent prognostic
- (12) Hanson RL and Hollingsworth MA. Functional consequences of differential O-glycosylation of MUC1, MUC4, and MUC16 (downstream effects on signaling). MDPI, Basel, Switzerland Biomolecules.2016;6(34): pp 1-12.
- (13) Schut IC, Waterfall PM, Ross M, O'Sullivan C, Miller WR, Habib FK et al. MUC1 expression, splice variant and short form transcription (MUC1/Z, MUC1/Y) in prostate cell lines and tissue. BJU International. 2003; 91(3): pp 278-83.
- (14) Garbar C, Mascaux C and Wespes E: Expression of MUC1 and sialyl-Tn in benign prostatic glands, high-grade prostate intraepithelial neoplasia and malignant prostatic glands: a preliminary study. Anal Quant Cytol Histol.2008; 30(2): pp 71-77.
- (15) Rabiau N, Dechelotte P, Guy L, Satih S, Bosviel R, Fontana L, et al. Immunohistochemical Staining of Mucin 1 in Prostate Tissues. In vivo International Journal of experimental and clinical Pathophysiology and drug research. 2009; 23(2):pp.203-07.
- (16) Strawbridge RJ, Nister M, Brisman K, Gronberg H and Li C. MUC1 as a putative prognostic marker for prostate cancer. Biomarker insight, 2008; 3: pp 303-15
- (17) Donald W.K. Targeting the human MUC1 oncoprotein: A tale of two proteins, Cancer Biology & Therapy. 2008;7(1). pp.81-84.
- (18) Kufe DW. MUC1-C in chronic inflammation and carcinogenesis; emergence as a target for cancer treatment. Carcinogenesis.oxford University Press. 2020; 41(9): pp 1173–83.